

The frontal cephalometric analysis – the forgotten perspective

Dr. Bradford Edgren delves into the benefits of the frontal analysis

When greeting a person for the first time, we are supposed to make direct eye contact and smile. But how often when you meet a person for the first time do you greet them towards the side of the face? Nonetheless, this is generally the only perspective by which orthodontists routinely evaluate their patients radiographically and cephalometrically. Rarely is a frontal radiograph and cephalometric analysis made, even though our first impression of that new patient is from the front, when we greet him/her for the first time.

A patient's own smile assessment is made in the mirror, from the facial perspective. It is also the same perspective by which he/she will ultimately decide if orthodontic treatment is a success or a failure. So why don't orthodontists utilize the frontal analysis more? B. Holly Broadbent is credited with developing the cephalometric procedure in 1931 when he simultaneously took frontal and lateral radiographs on his patients to evaluate the craniofacial skeleton in all three dimensions, including the posterior-anterior dimension. Interestingly, even though Broadbent took both frontal and lateral radiographs simultaneously, orthodontists are generally trained to use the lateral cephalometric analysis on all patients, but only encouraged to use the frontal analysis when an asymmetry is suspected or a dental crossbite is clinically observed. Accordingly, many orthodontists rarely assess a patient with a frontal

Educational aims and objectives

This article aims to discuss the frontal cephalometric analysis and its advantages in diagnosis.

Expected outcomes

Correctly answering the questions on page xx, worth 2 hours of CE, will demonstrate the reader can:

- Understand the value of the frontal analysis in orthodontic diagnosis.
- Recognize how the certain skeletal facial relationships can be detrimental to skeletal patterns that can affect orthodontic treatment.
- Realize how frontal analysis is helpful for evaluation of skeletal facial asymmetries.
- Identify the importance of properly diagnosing transverse discrepancies in all patients; especially the growing patient.
- Realize the necessity to take appropriate, updated records on all transfer patients.



cephalometric analysis.

Since all orthodontic patients are three-dimensional, they should be evaluated three-dimensionally, and the frontal analysis provides valuable information that should be part of the diagnostic process¹. Additionally, with the increasing use of Cone Beam Computed Tomography (CBCT) scans in orthodontics, a frontal analysis should be made for all patients receiving a CBCT scan; making use of the volume of information obtained. CBCT scans provide the opportunity for adjusting the orientation of the patient's head, improving the reliability of the cephalometric measurements, and simulating Broadbent's cephalometric procedure.

Skeletal facial asymmetries are more the rule than the exception, and the frontal analysis is an excellent instrument to use for their evaluation. However, skeletal asymmetries are not always readily visible clinically nor do skeletal lingual crossbite patterns reveal themselves with obvious posterior dental crossbites. It can be challenging to determine the presence of a skeletal lingual crossbite pattern when it appears that there is a normal transverse relationship between the upper and lower jaws without a frontal analysis. Many patients who appear to have normal transverse skeletal relationships have skeletal lingual crossbite patterns² that can negatively affect orthodontic treatment

outcomes. Furthermore, skeletal lingual crossbite patterns are not just limited to a narrow maxilla. Posterior skeletal lingual crossbites can also be the result of wide mandibles, which are further exacerbated by future, excessive lower jaw growth¹.

True dental asymmetries can be treated by orthodontics alone. However, prior to the initiation of treatment, the etiology of the dental asymmetry should be determined. If that dental asymmetry is the result of a skeletal issue, an orthopedic or surgical approach will be necessary because orthodontic treatment alone would likely result in an unfavorable outcome.

So, what about those skeletal asymmetries? It's not uncommon for the orthodontist to miss a skeletal asymmetry in a severely crowded and maligned malocclusion that only becomes obvious after the leveling and alignment phase of treatment³. At this stage in treatment, it may be more difficult to address the skeletal asymmetry and, therefore, more difficult to salvage. But, diagnosing the skeletal asymmetry initially, prior to the start of treatment, provides informed consent to the patient and reduces the unintended consequences of poor treatment planning.

Perfectly symmetrical faces are largely theoretical concepts that seldom exist in living organisms⁴. Minor facial asymmetries are relatively common. In a study by Severt and Proffit of 1,460 patients, 34% had a



Bradford Edgren, DDS, MS, earned both his Doctorate of Dental Surgery, as Valedictorian, and his Master of Science in Orthodontics from University of Iowa, College of Dentistry. He is a Diplomate, American Board of Orthodontics and an affiliate member of the SW Angle Society. Dr. Edgren has presented to numerous groups on the importance of cephalometrics, CBCT, and upper airway obstruction. He has been published in *AJODO*, *American Journal of Dentistry*, as well as other orthodontic publications. Dr. Edgren currently has a private practice in Greeley, Colorado.

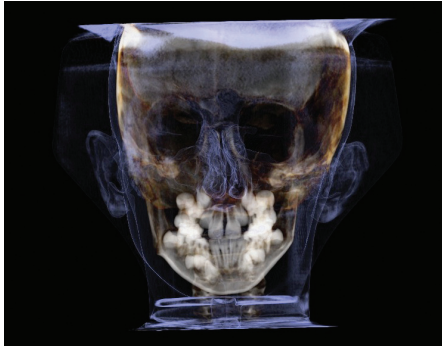


Figure 1: Posterior-anterior image demonstrating right-sided lateral and vertical facial asymmetries (CBCT images taken with i-CAT [Imaging Sciences International])

clinically apparent facial asymmetry. Of the facial asymmetries that were present, the upper face was only affected in 5%, the middle third (primarily the nose) in 36%, and the lower third in 74% of cases. Vertical asymmetries were present in 41% of cases⁵. Moreover, facial asymmetries are more frequently associated with Class II and Class III malocclusions than with Class I malocclusions⁴.

The frontal cephalometric analysis is useful in diagnosing skeletal asymmetries and skeletal crossbite patterns for both jaws. It is also aids in the evaluation of: occlusal cants, nasal widths, turbinate enlargements, dental arch widths, bucco-lingual angulation of first molars, angulation and position of impacted canines, location of the maxillary incisors to the skeletal midline, location of the mandibular incisors to the mandibular midline and skeletal midline, and the morphology of the maxilla and mandible. The frontal analysis can also aid in determining if an off-centered dental midline is due to a tooth-size discrepancy, a mandibular functional shift, or skeletal dysplasia.

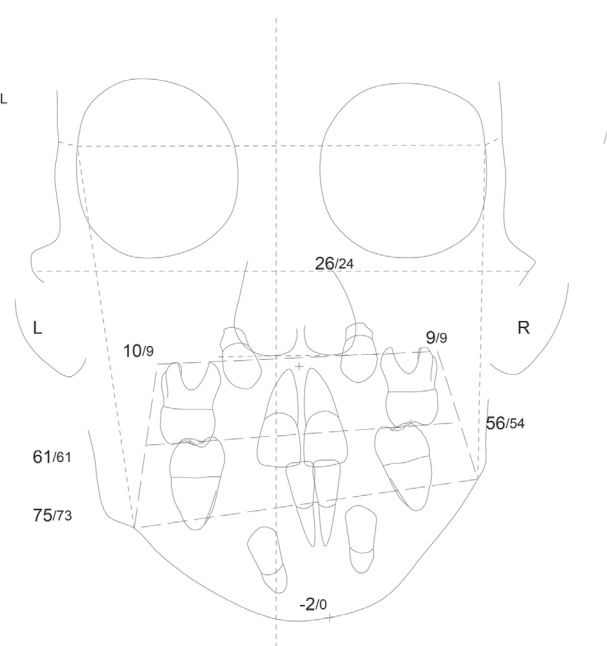
Significant skeletal asymmetries can be congenital, developmental, or acquired. Hemifacial microsomia is a congenital birth defect where the lower half of the face is typically unilaterally, or rarely bilaterally, underdeveloped. This common facial birth defect, second only to clefts, most frequently affects the ears, mouth, and lower jaw⁶. In this case, the patient has a significant unilateral dentofacial asymmetry to the right. Complete diagnostic records were taken, including a CBCT scan, followed by lateral and frontal cephalometric analyses. The frontal image and the corresponding cephalometric analysis demonstrate the effects of the hemifacial microsomia on the right side of the patient's face (Figures 1 and 2). The

DR. B.N. EDGREN
F (CA) Caucasian
AGE: 7.7 SKEL: 7.3
X: 07/30/2010 - R: 08/12/2010
MISSING PERMANENT TEETH

TRACING

BEFORE TREATMENT

RMO®



MEASURED VALUE/NORM

SIGNIFICANT CONSIDERATIONS			
CONDITION Md arch narrow compared to jaw Midline Asymmetry Positional Max-Mand asymmetry		REASON	
FACIAL PATTERN: DOLICHOFACIAL			
# FACTORS	MEASURED VALUE	NORM	CLINICAL DEVIATION
Intermolar Width (B6-B6)	55.8 mm	54.4 mm	0.7
Denture Midline	-2.3 mm	0.0 mm	-1.5 *
Max-Mand Width Left	-10.2 mm	-9.1 mm	-0.7
Max-Mand Width Right	-9.4 mm	-9.1 mm	-0.2
Denture to Jaw Midlines	0.6 mm	0.0 mm	0.4
Nasal Width	26.3 mm	24.4 mm	0.9
Maxillary Width (J-J)	61.0 mm	60.5 mm	0.2
Mandibular Width (AG-GA)	75.4 mm	72.9 mm	1.3 *

© RMO 2010

Figure 2: Frontal cephalometric analysis demonstrating significant dentofacial asymmetry to the right and occlusal cant

lateral radiographic image alone does not display the degree of the lateral and vertical asymmetries that could easily be passed off as poor patient positioning (Figure 3).

The panoramic radiograph demonstrated a hypoplastic right ramus and condyle (Figure 4). The maxillary canines and lateral incisors were ectopically erupting due to an anterior maxillary constriction.

Early interceptive treatment included rapid maxillary expansion followed by upper and lower fixed appliances. Following the removal of the fixed appliances at the end of early interceptive treatment, a CBCT scan was taken. The scan revealed an improvement in the facial asymmetry and significantly improved permanent tooth eruption and root parallelism (Figures

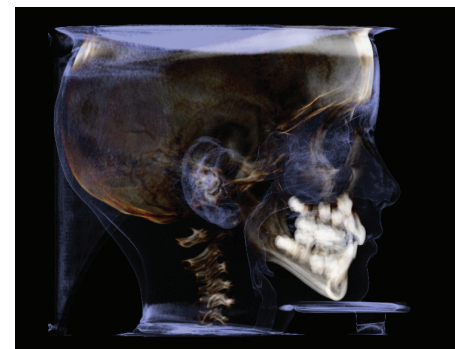


Figure 3: Lateral CBCT image

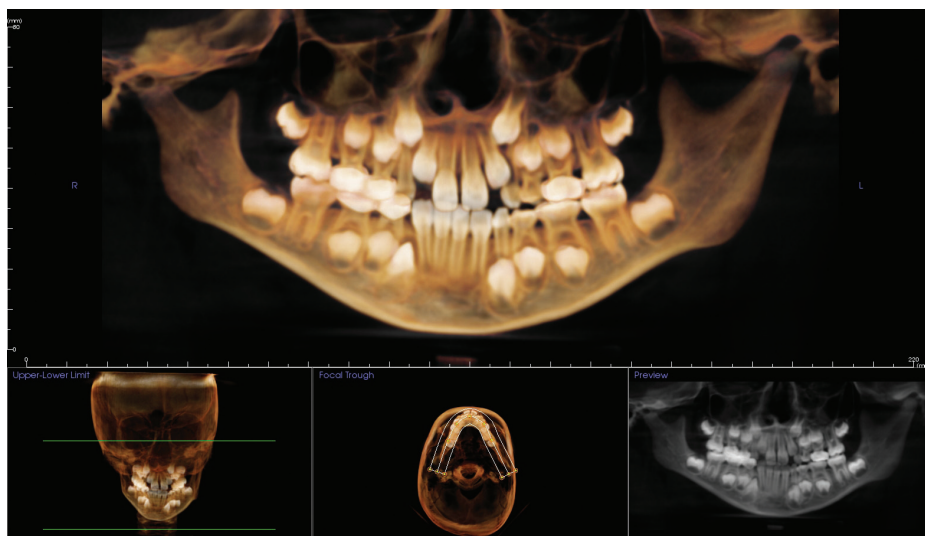


Figure 4: Panoramic image demonstrating a hypoplastic right condyle and ramus, and ectopic maxillary canines

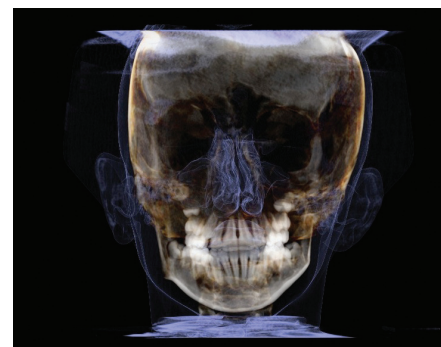

Figure 5: Posterior-anterior image following early interceptive treatment

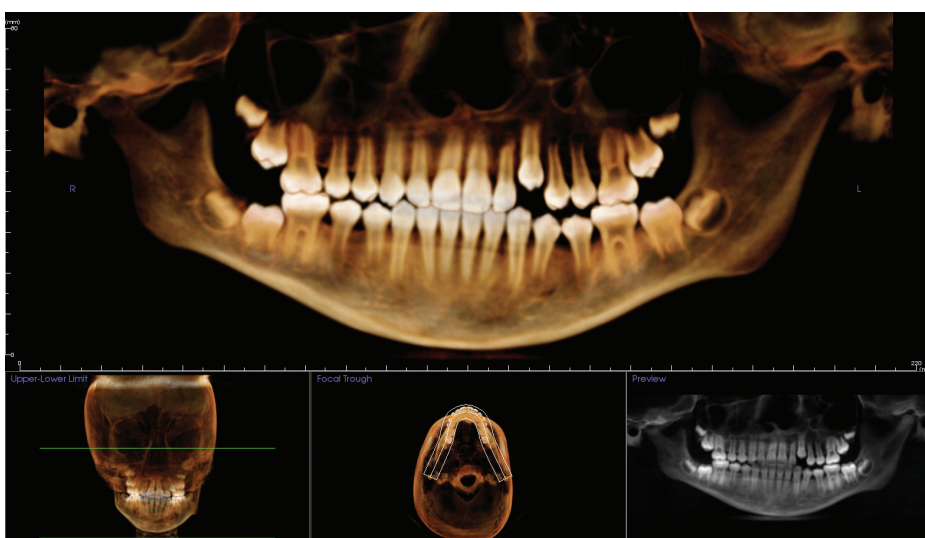


Figure 6: Panoramic image following early interceptive treatment. The anterior maxillary constriction has been resolved, and the maxillary canines have erupted nicely

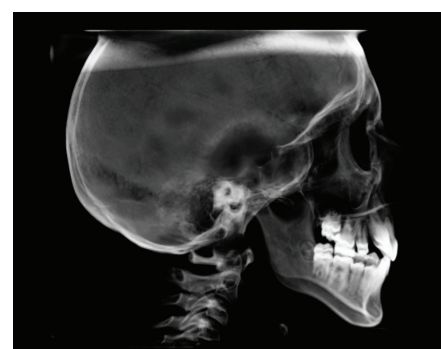


Figure 7: Note, in the lateral radiographic image, the difference in the borders of the left and right sides of the mandible. When the borders of the mandible present this large of a difference, and the orbits are aligned, a facial asymmetry should be suspected

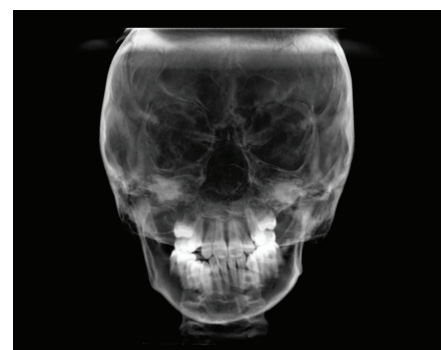

Figure 8: Posterior-anterior image revealing the significant right-sided vertical and lateral asymmetries

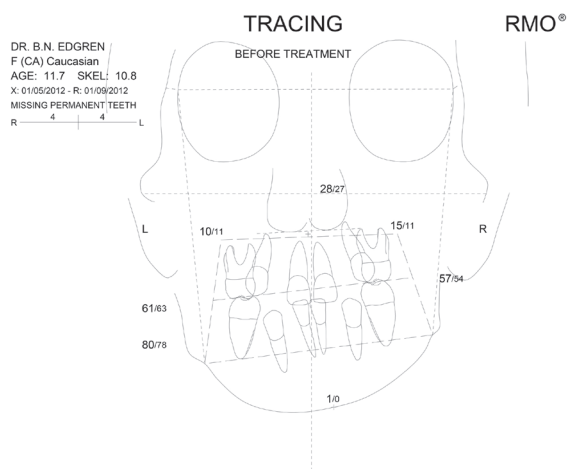
5 and 6). This patient will be monitored until the eruption of the permanent dentition is complete. Second phase treatment will include full fixed appliances and orthognathic surgery to correct the remaining asymmetries.

Condylar hypoplasia is the unilateral or bilateral underdevelopment of the mandibular condyle(s). Condylar hypoplasia can be either congenital or acquired, and is often associated with head and neck syndromes as in the previous case⁷. Bilateral condylar hypoplasia is considerably less common than unilateral involvement, even though both can lead to significant facial deformities. In acquired cases, the extent of the facial deformity is dependent upon the severity of the injury that caused the disruption in condylar growth, the duration of that injury, and the age that it occurred.⁸

This case of acquired condylar hypoplasia was a transfer into my office. She had had previous Phase I treatment, including the extraction of the maxillary first premolars. At her clinical exam, a right-sided facial asymmetry was noted. After taking progress records, which included a CBCT scan (Figures 7 and 8), both lateral and frontal cephalometric analyses were made. A frontal analysis revealed a severe mandibular asymmetry to the right, a right vertical asymmetry, as well as a skeletal lingual crossbite pattern due to both jaws (Figure 9). The mandibular asymmetry amounted to a total of 8 mm to the patient's right. The source of the asymmetry was a hypoplastic right condyle. The patient's right ramus was also significantly shorter and comparatively broader when compared to the left. Since this patient still has several years left to grow, the facial asymmetry will

most likely become more pronounced.

The best solution for this patient is maxillary expansion, leveling and aligning, and eventually orthognathic surgery to correct the facial asymmetry. Note, this is a case where the significant facial asymmetry and the skeletal lingual crossbite were not documented until a frontal analysis was made. Consequently, this case is a perfect example of where a facial asymmetry



MEASURED VALUE/NORM

SIGNIFICANT CONSIDERATIONS			
CONDITION		REASON	
Skel Lingual Crossbite pattern		due to the maxilla & mandible	
Midline Asymmetry		due to skel asymmetry-mandible	
Positional Max-Mand asymmetry			
FACIAL PATTERN: DOLICHOFACIAL			
# FACTORS	MEASURED VALUE	NORM	CLINICAL DEVIATION
Intermolar Width (B6-B6)	57.0 mm	54.0 mm	1.5 *
Denture Midline	1.4 mm	0.0 mm	1.0 *
Max-Mand Width Left	-9.8 mm	-11.0 mm	0.8
Max-Mand Width Right	-15.2 mm	-11.0 mm	-2.8 **
Denture to Jaw Midlines	-3.3 mm	0.0 mm	-2.2 **
Nasal Width	27.7 mm	26.8 mm	0.5
Maxillary Width (J-J)	61.5 mm	62.8 mm	-0.7
Mandibular Width (AG-GA)	80.0 mm	78.3 mm	0.9

© RMO 2012

Figure 9: Posterior-anterior image revealing the significant right-sided vertical and lateral asymmetries

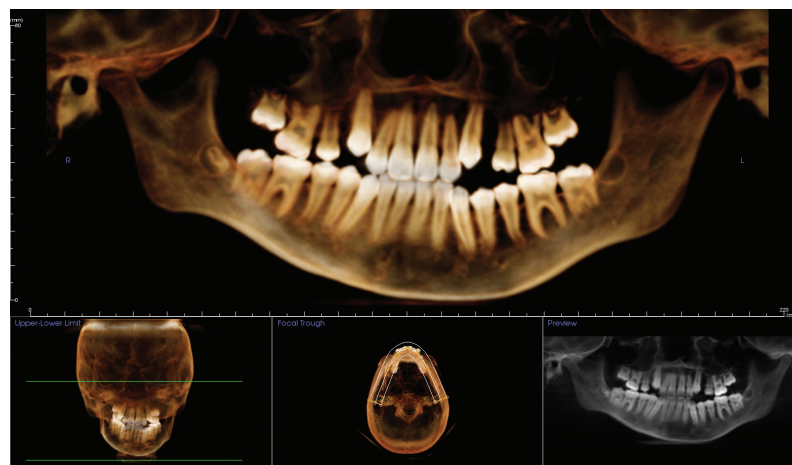


Figure 10: Panoramic image exhibiting condylar hypoplasia of the right condyle and subsequent widening of the ramus. The patient's maxillary first premolars were extracted to aid in the eruption of the maxillary canines. If expansion had been performed on this patient initially, it may have been unnecessary to extract the maxillary first premolars to make room for the eruption of the canines

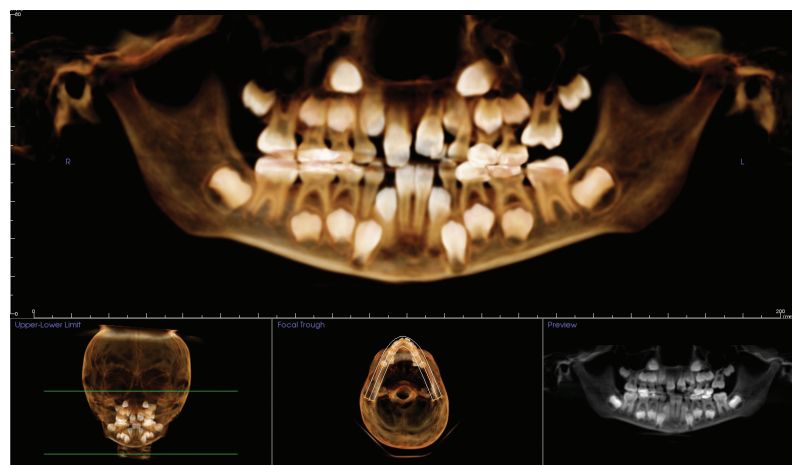


Figure 11: Initial panoramic image exhibiting severe crowding and multiple impacted teeth

went undiagnosed until the frontal analysis was made, after irreversible orthodontic treatment had been already initiated, including extractions of permanent teeth. It only disputes the myth that the frontal analysis should only be made if an asymmetry is suspected. Obviously, significant facial asymmetries do exist and can be missed without a posterior-anterior radiograph and subsequent analysis. Routinely taking a posterior-anterior radiograph reduces the chances of missing an asymmetry. Even this patient's panoramic image illustrates the extent of the right condylar hypoplasia, shortened ramus, and noticeable asymmetry (Figure 10).

This case also illustrates why it is necessary to take appropriate, updated records on all transfer patients. I have found previously undiagnosed tumors, severe facial asymmetries, cysts, supernumeraries, and other pathologies

that required attention before continuing orthodontic treatment in patients already in orthodontic appliances.

Like facial asymmetries, skeletal lingual crossbites due to either the maxilla and/or mandible are more the norm than the exception. Transverse maxillary constrictions frequently result in significant crowding and impacted teeth. This 7.3-year-old Caucasian female presented with loss of arch length in both arches due to premature loss of the deciduous lateral incisors. The left maxillary molar was ectopically erupting and had resorbed the distal root of the left maxillary second deciduous molar, blocking out the eruption path of the second premolar (Figure 11). But, it was the patient's overall pre-existing maxillary deficiency, including the transverse constriction, that was the original source for the loss of maxillary arch length, severe crowding, disruption of the eruption of the maxillary laterals,

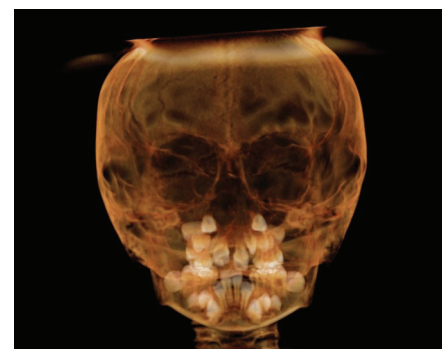


Figure 12: Initial posterior-anterior image. Note the significant rotation of the right maxillary incisor

and subsequent impaction of the maxillary canines.

A posterior-anterior image taken from the diagnostic CBCT scan of the patient demonstrates the significant rotation of the maxillary lateral incisors and severe maxillary anterior crowding (Figure 12). The frontal cephalometric analysis not only illustrated a dental lingual crossbite pattern

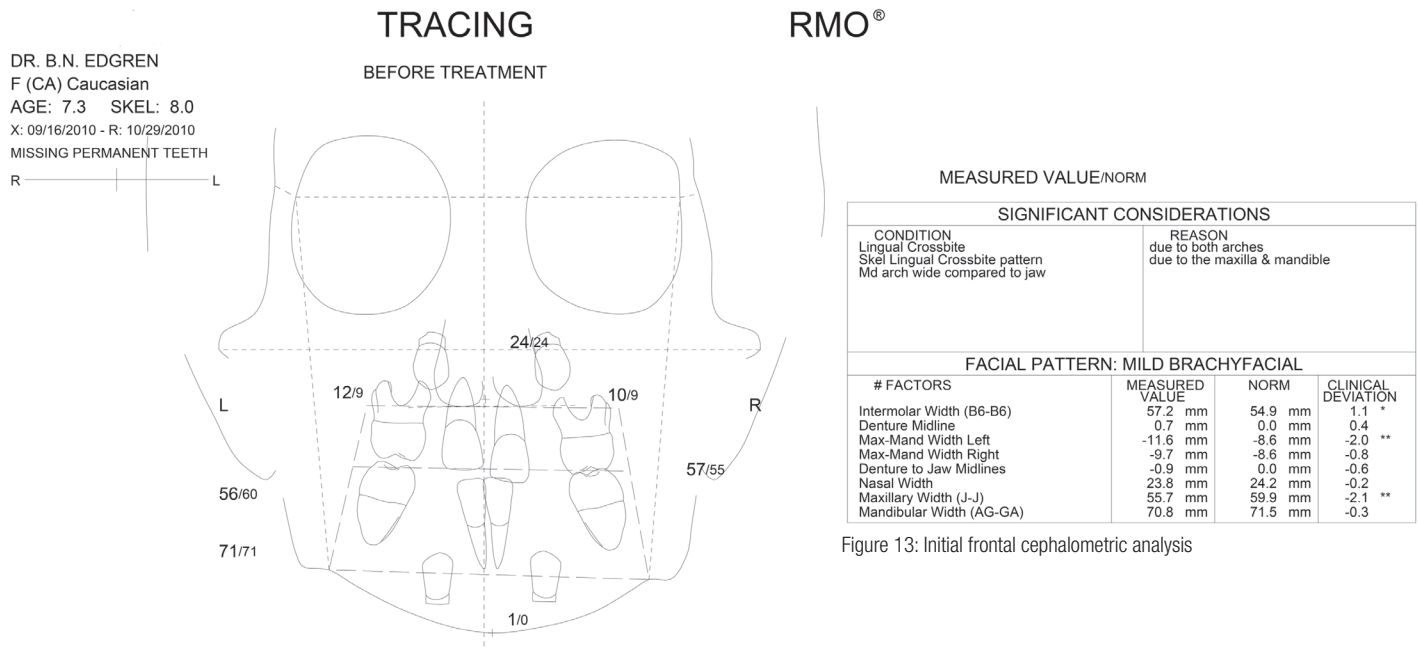


Figure 13: Initial frontal cephalometric analysis

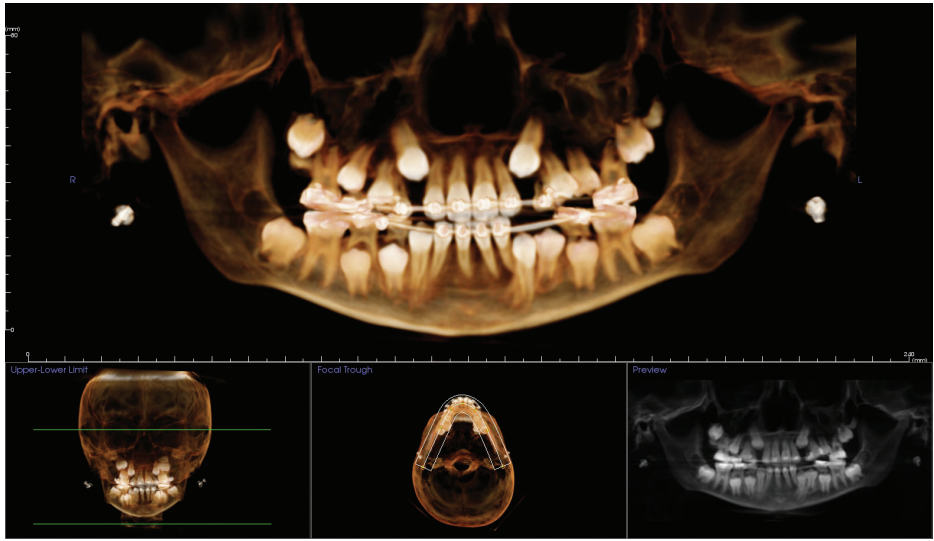


Figure 14: Progress panoramic image exhibiting improved eruption of the maxillary canines and the erupted lateral incisors with complete root formation. Also, note maxillary right third molar blocking the eruption of the maxillary right second molar

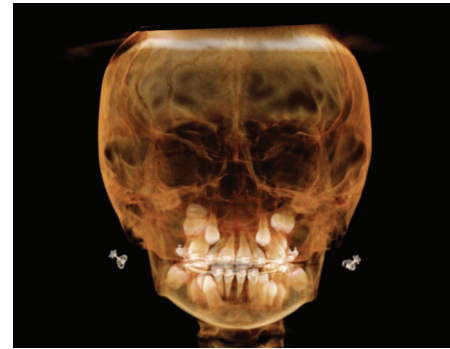

Figure 15: Progress posterior-anterior image. Note the significantly improved angulation of the maxillary canines and lateral incisors

due to both arches but also a skeletal lingual crossbite pattern due to the maxilla and mandible (Figure 13). After distalization of the maxillary left first molar, the patient was expanded with a bonded expansion appliance to correct the dental and skeletal lingual crossbite patterns.

After 29 months of Phase I treatment, the maxillary and mandibular lateral incisors have erupted into proper position, and the maxillary canines are erupting appropriately (Figures 14 and 15). Early extraction of the maxillary deciduous canines was not necessary, nor was it indicated. Studies have suggested that impacted canines are a result of maxillary constriction, and rapid maxillary expansion can aid in the proper eruption on maxillary canines.^{9,10,11}

Orthodontic treatment without expansion, when a transverse maxillary constriction exists, does not address the root of the problem. Extraction of permanent teeth in a growing patient, to promote eruption of the maxillary canines, may result in future crossbite patterns when the patient becomes an adult and dentofacial growth is complete. A case that appears to be treated to proper balance may indeed become a significant malocclusion years later because future growth and the skeletal lingual crossbite patterns were never addressed, nor treated.⁸

This adult case exemplifies the importance of properly diagnosing transverse discrepancies in all patients and especially in the growing patient.

This 30-year-old Caucasian, female patient presented with a chief complaint of myofascial pain disorder (MPD) and an anterior open bite. Her maxillary first premolars were extracted as a child as part of her orthodontic treatment. However, what may have been a well-treated case at the finish as an adolescent became a significant problem as an adult. Because her skeletal lingual crossbite pattern was never initially diagnosed, extraction of the first permanent premolars negatively enhanced her transverse discrepancy. Additional facial growth only intensified her transverse discrepancies. Over time, this patient developed an anterior open bite and crossbite, bilateral posterior crossbites, gingival recession, and MPD (Figures 16

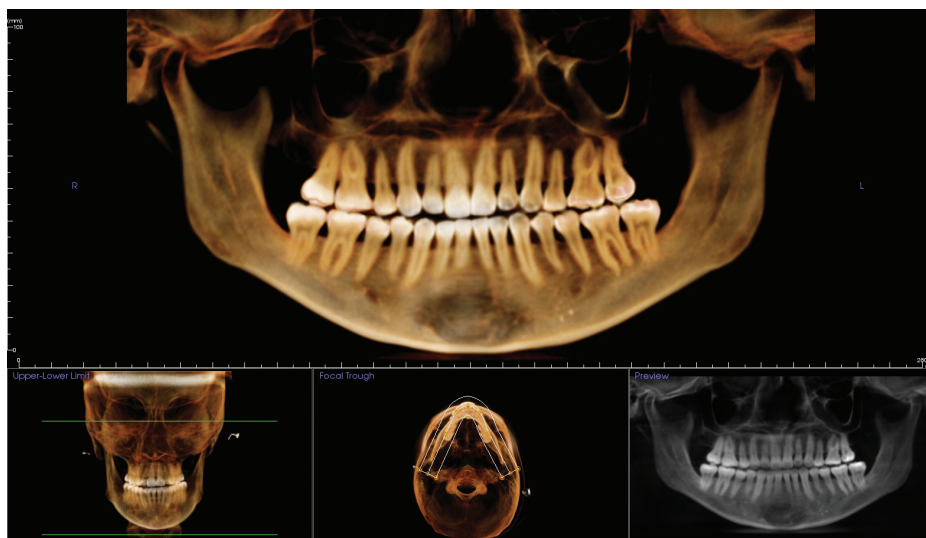


Figure 16: Panoramic image demonstrating anterior open bite

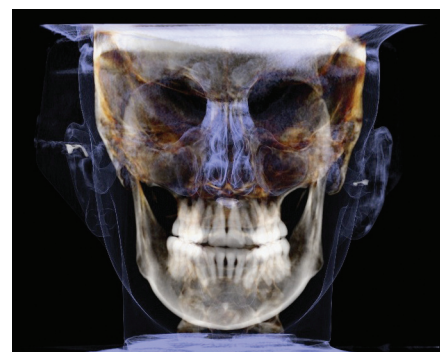

Figure 17: Posterior-anterior image demonstrating bilateral posterior crossbites and anterior open bite

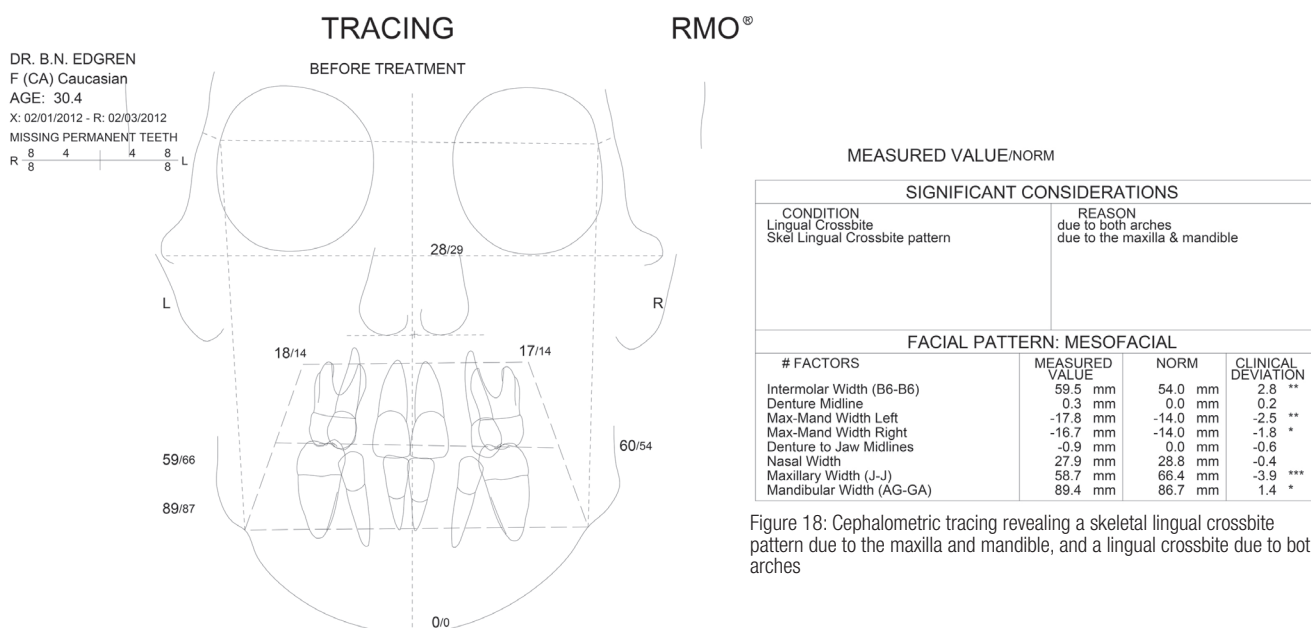


Figure 18: Cephalometric tracing revealing a skeletal lingual crossbite pattern due to the maxilla and mandible, and a lingual crossbite due to both arches

and 17). The frontal analysis made from her CBCT scan revealed a significantly narrow maxilla and a wide mandible (Figure 18), indicating that rapid maxillary expansion would have been a more appropriate treatment regimen than extraction of teeth.

The patient is currently being treated for her myofascial pain disorder. Future treatment will focus on improving her periodontal condition and a combined surgical orthodontic approach to address her orthodontic problems.

The use of the frontal analysis should be more the norm than the exception. Many facial asymmetries and skeletal lingual crossbite patterns go undiagnosed, only becoming apparent later and adversely affecting the quality of care. Performing a frontal analysis may take more time, but it is in the best interest of the patient.

Remember, the patient will be making his/her own quality assessment of the final

orthodontic result, using a frontal analysis called the mirror. **OP**

REFERENCES

- Edgren BN. The combined value of the frontal analysis and growth prediction. *Orthotown*. 2013;56-57.
- Miner RM, Al Qabandi S, Rigali PH, Will LA. Cone-beam computed tomography transverse analysis. Part 1: Normative data. *Am J Orthod Dentofacial Orthop*. 2012;142(3):300-307.
- Ricketts RM, Grummons D. Frontal cephalometrics: practical applications, part I. *World J Orthod*. 2003;4(4):297-316.
- Cheong YW, Lo LJ. Facial asymmetry: etiology, evaluation, and management. *Chang Gung Med J*. 2011;34(4):341-351.
- Severt TR, Proffit WR. The prevalence of facial asymmetry in the dentofacial deformities population at the University of North Carolina. *Int J Adult Orthodon Orthognath Surg*. 1997;12(3):171-176.
- The National Craniofacial Association. Hemifacial Microsomia. <http://www.faces-cranio.org/Disord/Hemi.htm>. Accessed August 19, 2013.
- Neville BW, Damm DD, Allen CM, Bouquot JE. *Oral and Maxillofacial Pathology*. Philadelphia, PA: W.B. Saunders; 1995:16.
- Edgren BN. Upper airway obstruction - poor function becomes poor form. *Orthodontic Practice US*. 2013;4(2):34-37.
- McConnell TL, Hoffman DL, Forbes DP, Janzen EK, Weintraub NH. Maxillary canine impaction in patients with transverse maxillary deficiency. *ASDC J Dent Child*. 1996;63(3):190-195.
- Schindel RH, Duffy SL. Maxillary transverse discrepancies and potentially impacted maxillary canines in mixed-dentition patients. *Angle Orthod*. 2007;77(3):430-435.
- Baccetti T, Mucedero M, Leonardi M, Cozza P. Interceptive treatment of palatal impaction of maxillary canines with rapid maxillary expansion: a randomized clinical trial. *Am J Orthod Dentofacial Orthop*. 2009;136(5):657-661.